

STRATOS™

ENDOSCOPIC RELEASE SYSTEM

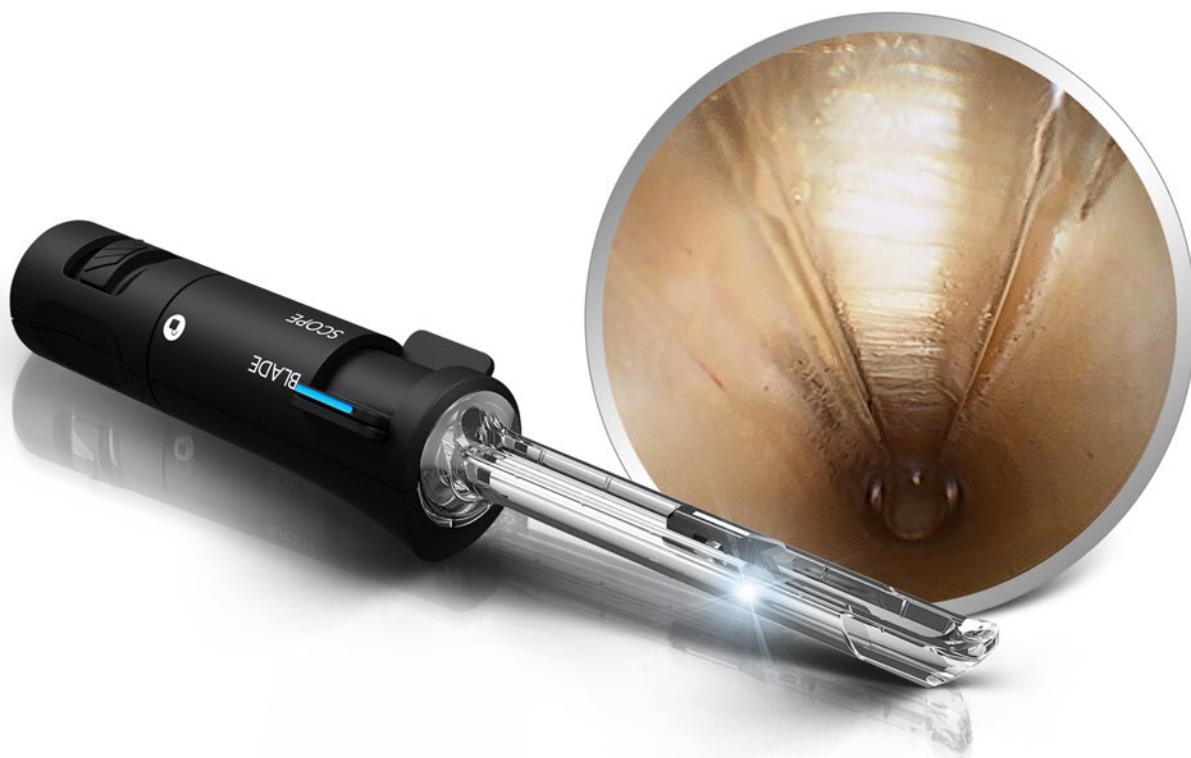Endoscopic Carpal Tunnel Release

Surgical Technique

Proximal Portal

Contributing Surgeons

Blane Sessions, MD ■ Ather Mirza, MD



STRATOS™

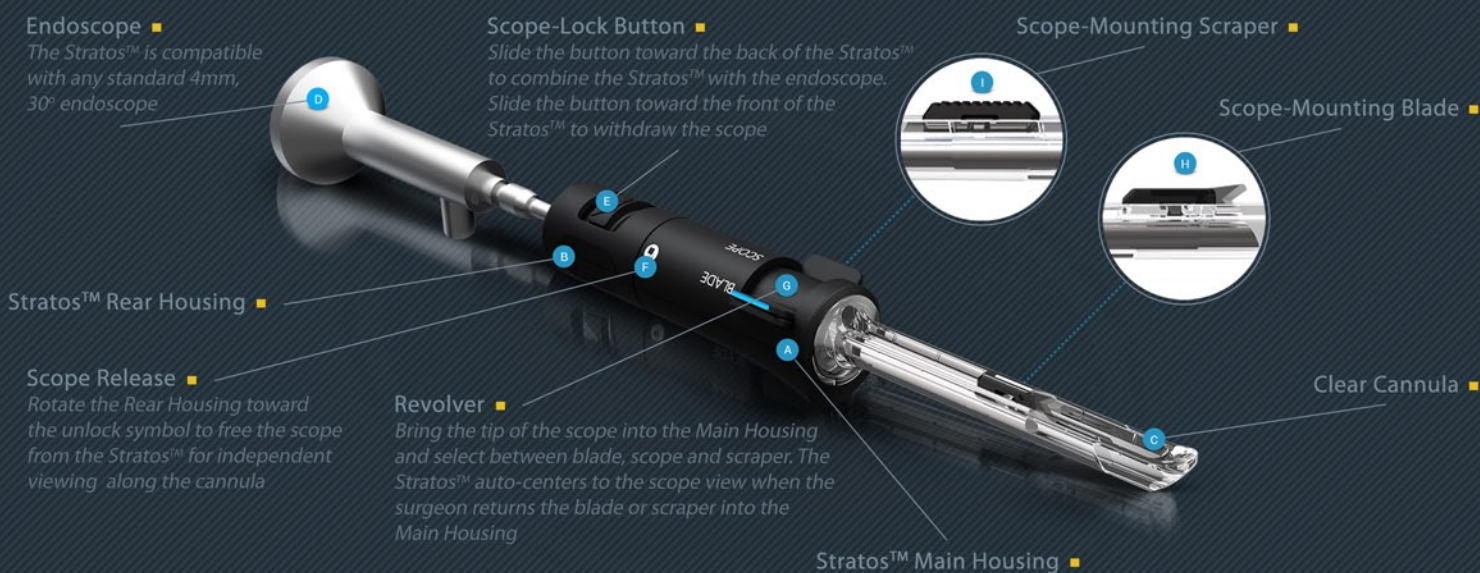
ENDOSCOPIC RELEASE SYSTEM

Stratos™ Endoscopic Release System

The Stratos™ Endoscopic Release System is an all-in-one, disposable device designed to approach endoscopic carpal tunnel release from a distal or proximal, single portal. The Stratos™ features a next generation clear cannula for unparalleled endoscopic visualization and workability within the carpal tunnel. It combines with any standard 4mm, 30° endoscope allowing the surgeon to steer the device into position under endoscopic control. The scope works independent of the device to confirm key anatomy is completely protected along the length of the cannula prior to release. Add to these features a deployable blade and synovial scraper, and the Stratos™ is arguably the safest, most comprehensive system available to surgeons.

Device Overview

The Stratos™ is compatible with any standard 4mm, 30° endoscope.



Indications for Endoscopic Carpal Tunnel Release

Endoscopic carpal tunnel release surgery is indicated in the majority of patients who fail to respond to conservative treatment of carpal tunnel syndrome.

Contraindications for Endoscopic Carpal tunnel Release

Surgeons should follow the general contraindications applicable to open carpal tunnel release when considering a patient for endoscopic carpal tunnel release. In addition, patients with stiff wrists, suspected space occupying lesions, or other anatomical abnormalities should be excluded.

Training

For safe and effective use, surgeons must possess a thorough knowledge and understanding of wrist anatomy and endoscopic technique using this instrumentation. Instructional video and cadaver workshops are available through A.M. Surgical.

For more information contact us at 800-437-9653 or info@amsurgical.com.

STRATOS™

ENDOSCOPIC RELEASE SYSTEM



PROCEDURE SETUP //

Instrumentation

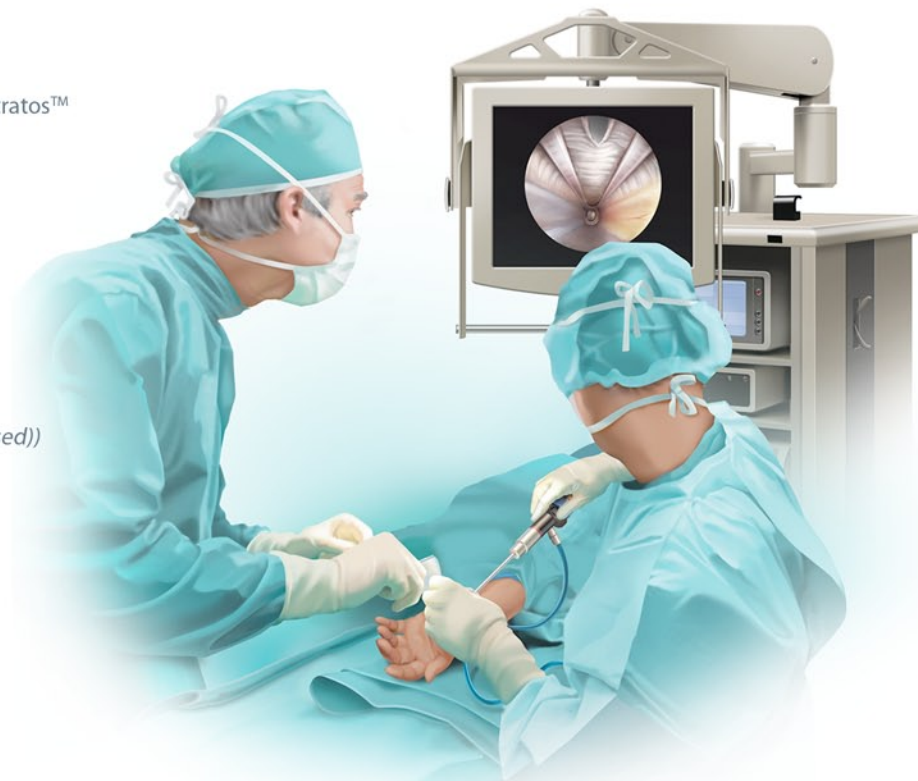The following instrumentation is recommended for the Stratos™ Endoscopic Carpal Tunnel Release procedure:

From A.M. Surgical

- Stratos™ (disposable)
- A.M. Surgical fascial elevator
- A.M. Surgical dilators

From the facility

- 4mm, 30° endoscope (standard shoulder and knee)
- Endoscopy tower setup (camera, light cord, (no fluid used))
- Marking pen
- #15 blade/blade handle
- Tenotomy scissors
- Freer elevator
- 2 Ragnell retractors
- Adson forceps
- Curved hemostat
- 2 double-pronged skin hooks
- 2 Senn retractors
- Scope defogger (FRED)



Positioning and Preparation

The patient is supine on the operating table with the operative hand palm up and resting on an arm board. The surgeon may prefer to perform the procedure with a towel roll underneath the wrist for slight extension. A tourniquet is recommended and the arm is sterile draped in a manner allowing for exsanguination of the hand and forearm using an Esmarch bandage.

Anesthesia

General or regional anesthesia is recommended for best endoscopic visualization. Once the surgeon has gained experience with the procedure, local anesthesia may be used.

When using local anesthesia, avoid injecting fluid into the carpal tunnel as it may obscure endoscopic visualization. The majority of local anesthesia should be administered subcutaneously in the wrist crease between the flexor carpi radialis and flexor carpi ulnaris. The remainder is administered along the track of the incision and superficial to the transverse carpal ligament.

STRATOS™

ENDOSCOPIC RELEASE SYSTEM

OPERATIVE TECHNIQUE

Marking the Skin

Mark out the following anatomical landmarks prior to elevating the tourniquet:

- Flexor carpi radialis
- Flexor carpi ulnaris
- Palmaris longus (*if present*)
- Hook of hamate
- A line from the middle of the wrist flexion crease to the base of the ring finger

Mark a 1.5 – 2cm transverse incision at one of the wrist flexion creases between the flexor carpi radialis and the flexor carpi ulnaris. The distal wrist crease typically presents subcutaneous fat but may be more desirable for cosmesis and direct access to the carpal tunnel. (*Figure 1*)

Incision and Dissection

Incise the skin and dissect through the subcutaneous tissue in a longitudinal manner. Superficial vessels are common at this location and hemostasis is achieved through electrocautery.

Care should be taken to identify and retract the palmar cutaneous branch of median nerve and/or the palmaris longus radially, if either structure is present. (*Figure 2, 2a*)

Continue dissection to the forearm fascia. (*Figure 3*)

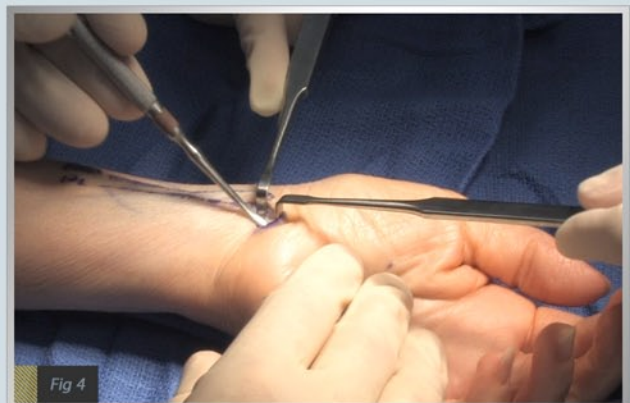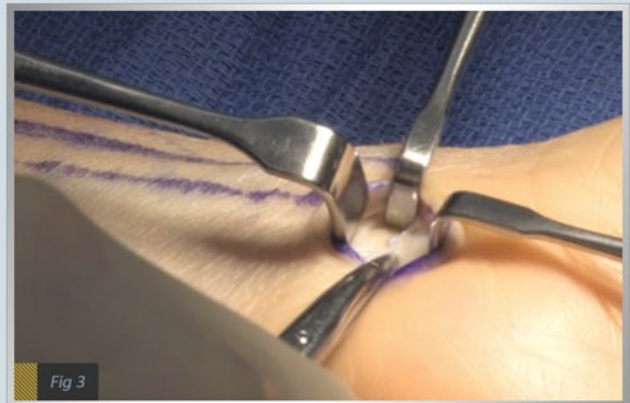
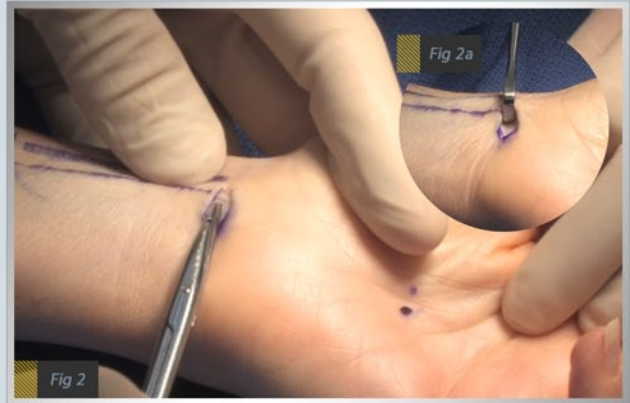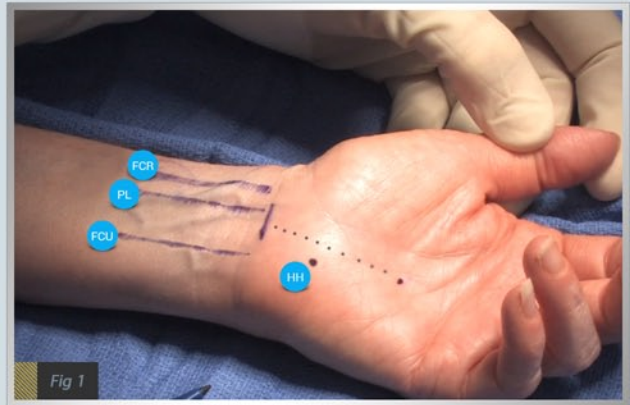
Preparing the Extrabursal Pathway

Make a transverse incision in the forearm fascia and create a plane between the undersurface of the transverse carpal ligament and ulnar bursa. Entry into the carpal tunnel is now possible and the median nerve should be identified.

Lift the forearm fascia using a ragnell or skin hook and introduce the fascial elevator into the carpal tunnel. (*Figure 4*)

Several passes of the elevator along the undersurface of the ligament is recommended to effectively clear synovium prior to introducing the Stratos™. Aim toward the base of the ring finger for proper positioning. Palpate the distal edge of the ligament with the non-operative hand to appreciate the distal extent.

Note: Passing a series of dilators is optional to further define the pathway underneath the transverse carpal ligament.



STRATOS™

ENDOSCOPIC RELEASE SYSTEM

Introducing Stratos™ into the Carpal Tunnel

With the pathway defined, combine the Stratos™ with any standard 4mm, 30° endoscope by sliding the *Scope-Lock* button toward the back of the device and advancing the scope through the Stratos™. (**Figure 5**) View the monitor to position the tip of the scope at the end of the clear cannula for optimal visualization. Release the *Scope-Lock* button to secure the Stratos™.

Note: If it becomes necessary to remove the endoscope from the Stratos™, slide the *Scope-Lock* button toward the front of the device and withdraw the scope.

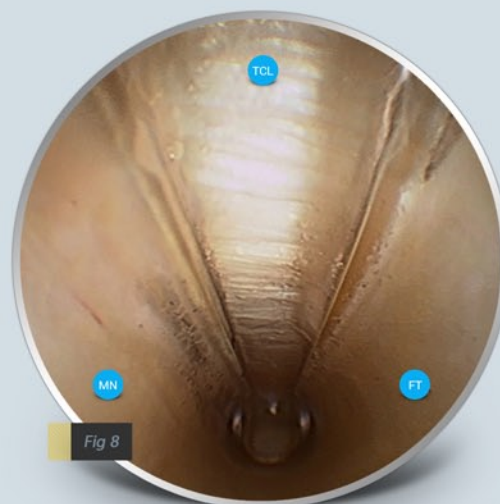
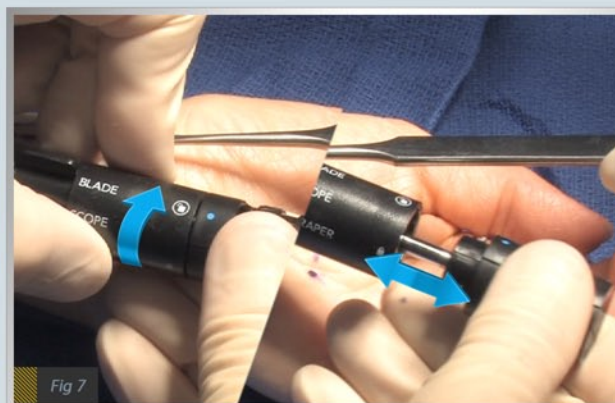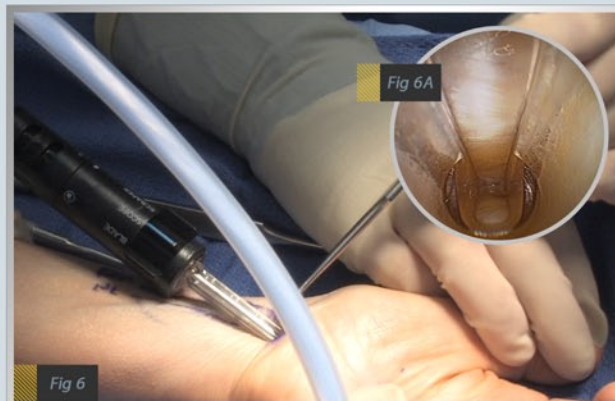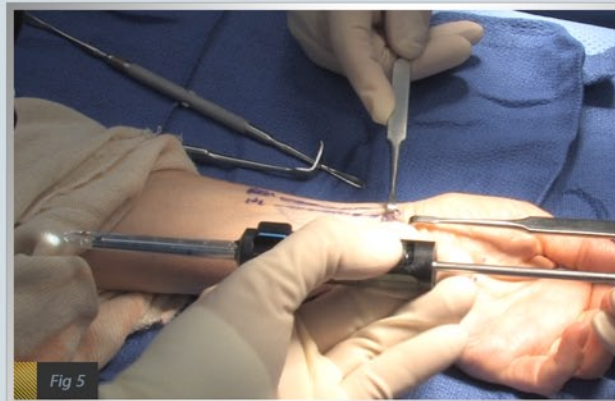
With the wrist in slight extension, advance the Stratos™ distally into the carpal tunnel, while hugging the undersurface of the transverse carpal ligament. (**Figure 6**) Care is taken to aim toward the base of the ring finger. The Stratos™ cannula tip should extend to the distal edge of the ligament. The surgeon can appreciate when the tip of the Stratos™ has reached the distal extent by viewing the monitor (**Figure 6A**), in addition to palpating the distal end with the non-operative hand. If the palmar fat pad is obstructing the view at the distal end, pass the Stratos™ cannula tip back and forth to define the ligament edge.

Note: To prevent fogging during the procedure, apply scope-defogger to the endoscope prior to assembling the Stratos™.

Endoscopic Visualization of Anatomy

With the Stratos™ in position, free the scope from the device by rotating the *Rear Housing* to the unlock symbol. (**Figure 7**) The Stratos™ cannula and *Main Housing* remain in position, while the scope moves independently. View the entire length of the clear cannula taking notice of the transverse carpal ligament fibers within the slot of the cannula, the median nerve protected on the radial side and the flexor tendon(s) protected on the ulnar side. (**Figure 8**) With no intervening structures in the cannula slot, deploy the blade to divide the transverse carpal ligament. (Continue to *Dividing the Transverse Carpal Ligament*)

If it's necessary to clear additional synovium from the undersurface of the ligament, a scraping tool within the Stratos™ can be deployed. (Continued on next page)



STRATOS™

ENDOSCOPIC RELEASE SYSTEM

Endoscopic Visualization of Anatomy (continued)

Note: Care should be taken to rule out any intervening structures are within the cannula slot prior to deploying the scraper.

To deploy the scraper, bring the tip of scope into the *Main Housing* of the Stratos™ until an “audible” click is felt. (**Figure 9**) The scraper can now be seen on the monitor. (**Figure 9A**) Push the tab of the *Revolver* toward the *SCRAPER* position to select the tool. Pass the scraper back and forth to define the view. To return to the scope view, pull the scraper back into the *Main Housing*. There is no need to push the tab back to the scope selection as the transition happens automatically.

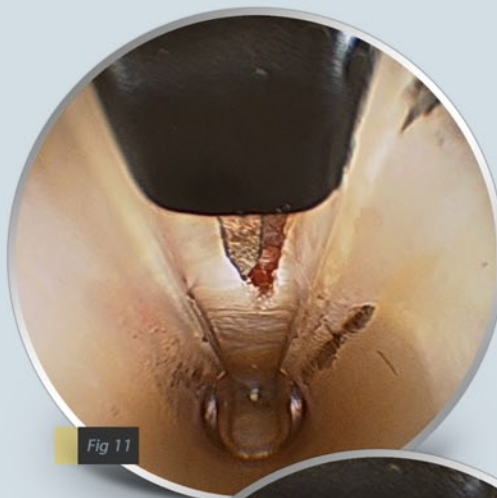
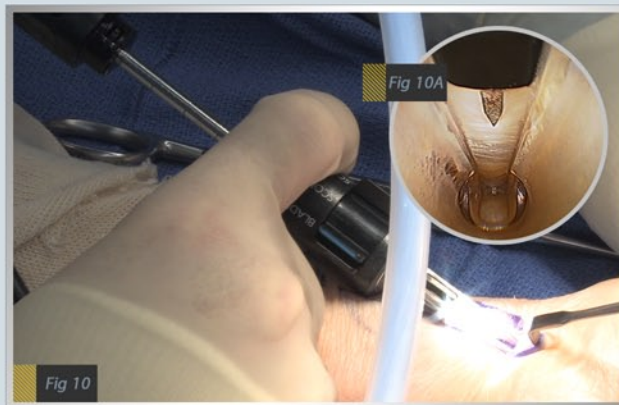
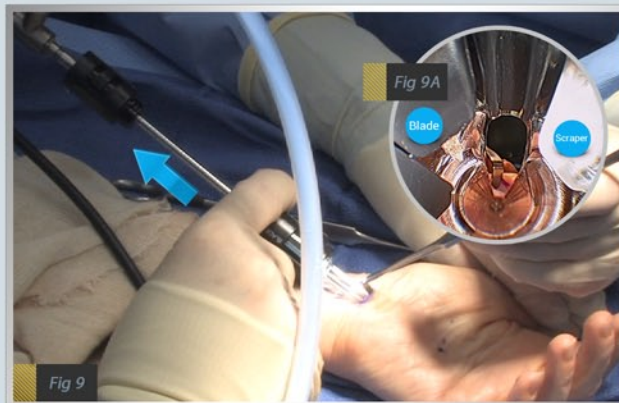
Other options for clearing synovium

- Pass the tip of the Stratos™ cannula back and forth along the ligament to further define the view.
- Or, remove the Stratos™ and pass the fascial elevator again.

Dividing the Transverse Carpal Ligament

With no intervening structures in the cannula slot, deploy the blade by bringing the tip of the scope into the *Main Housing* of the Stratos™, and selecting *BLADE* on the *Revolver*. The blade/scope assembly can now be observed on the monitor. Advance the blade in a controlled manner along the length of the cannula to divide the transverse carpal ligament. (**Figure 10, 10A**) As the blade approaches the distal edge, the scope can be withdrawn a few millimeters to appreciate intact fibers of the ligament. (**Figure 11**) Advance the blade stepwise until the distal ligament fibers are released. (**Figure 12**) The cut leaflets of the ligament should be appreciated and observed as two distinct parallel lines.

Note: The Stratos™ is intentionally designed to offer a clean, forward working view during division of the ligament by keeping subcutaneous tissue above the slot. Withdrawing the scope more than a few millimeters during the release may introduce subcutaneous tissue into the scope view.



STRATOS™

ENDOSCOPIC RELEASE SYSTEM

Verifying the Division

Return the blade to the *Main Housing* of the Stratos™ and reintroduce the scope into the clear cannula to ensure a complete release. Visualize and inspect the radial and ulnar leaflets as well as the distal extent of the transverse carpal ligament. (*Figure 13, 14*) If necessary, the blade can be reintroduced to complete the release.

The median nerve and flexor tendons can be appreciated through the clear cannula with the option of rotating the cannula slot onto the structures for further inspection.

The tip of the clear cannula can also be used to explore the distal extent of the release.

Upon verification of division, remove the Stratos™ from the carpal tunnel.

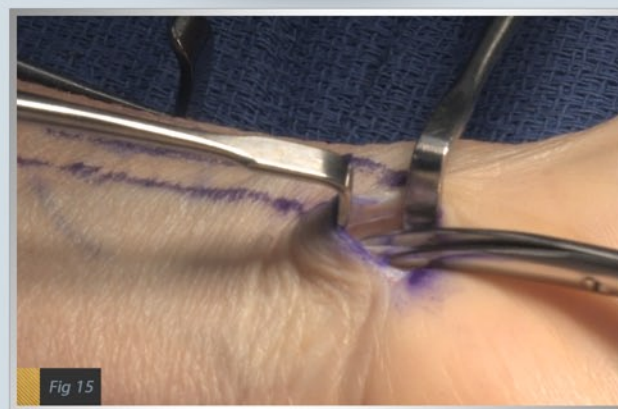
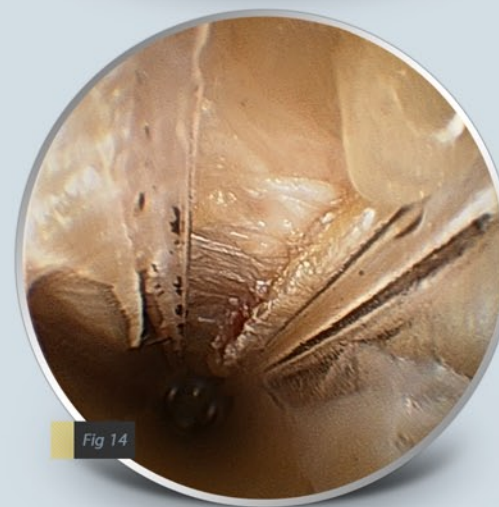
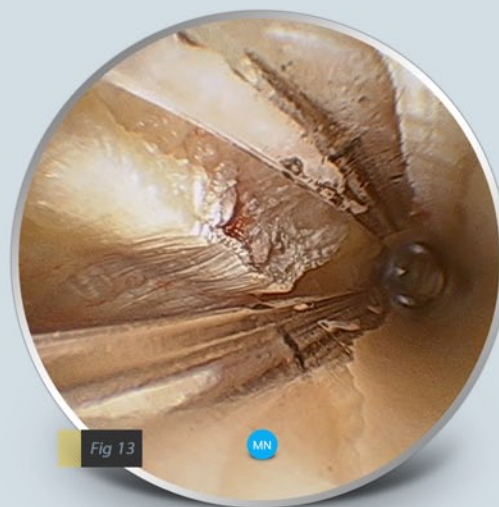
Dividing the Forearm Fascia

If desired the forearm fascia can be released to further decompress the median nerve. Create superficial and deep planes around the forearm fascia proximal to the incision and take care to protect the median nerve. Pass tenotomy scissors to release the fascia proximally. (*Figure 15*)

Closing the Wound and Postoperative Care

Irrigate and close the wound using a running subcuticular technique and apply a soft dressing. The soft dressing can be removed a few days following surgery and a band-aid applied thereafter for 5-7 days.

The patient is encouraged to perform finger range of motion exercises following surgery and return to normal activities as tolerated. The patient is asked to avoid heavy work or activities for a period of 4-6 weeks. Return to work varies.



STRATOS™

ENDOSCOPIC RELEASE SYSTEM

Disposables

#5500-B	Stratos - Endoscopic Release System (Box of 5)
#5500-K	Stratos - Endoscopic Release System (Box of 5, Straps/PadKit)
#5500	Stratos - Endoscopic Release System (Single)

Instrumentation

9600-06	Fascial Elevator	9600-08	Dilator - Medium
9600-07	Dilator - Small	9600-09	Dilator - Large



A.M. Surgical, Inc.
290 East Main St, Ste 200, Smithtown, NY 11787
Phone: 800-437-9653 Fax: 631-980-4369
E-mail: info@amsurgical.com
www.amsurgical.com/stratos